

Corneal deposits secondary to ciprofloxacin eye drops

Category(ies): Cornea

Contributor: [Elizabeth Gauger, MD](#) and [Anna Kitzmann, MD](#)

Photographer: 1st image: Brice Critser, CRA; 2nd image: Stefani Karakas, CRA



45-year-old female with Pseudomonas keratitis who developed corneal deposits secondary to topical ciprofloxacin use. The deposits usually resolve on their own over time.

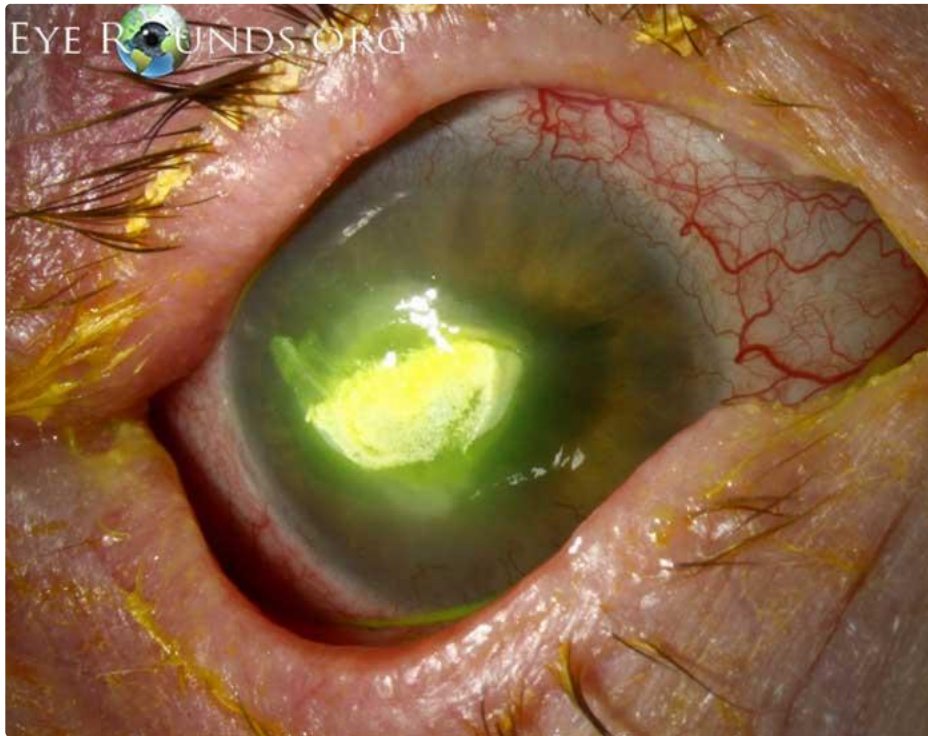
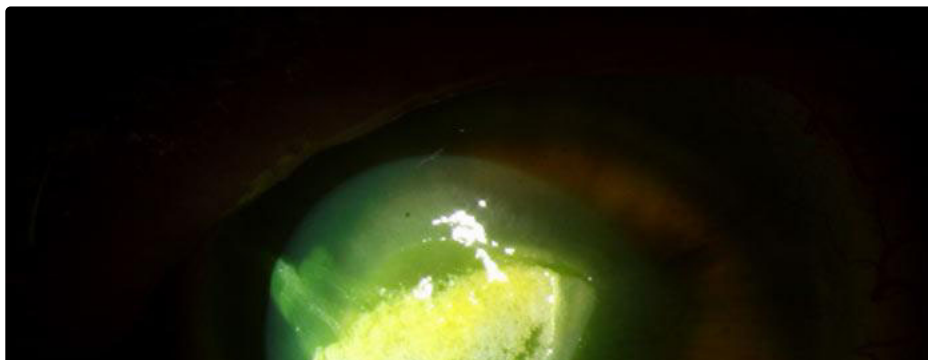


Image: Brice Critser, CRA

[Enlarge](#) [Download](#)



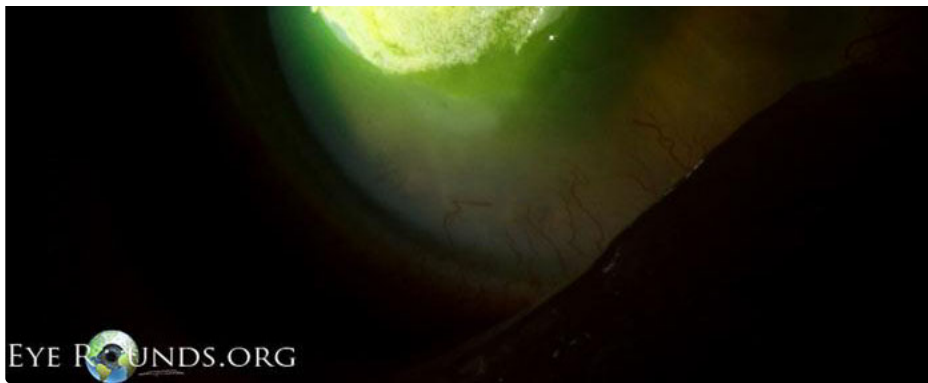


Image: Stefani Karakas, CRA

[Enlarge](#) [Download](#)

Image Permissions:



Ophthalmic Atlas Images by [EyeRounds.org](#), [The University of Iowa](#) are licensed under a [Creative Commons Attribution-NonCommercial-NoDerivs 3.0 Unported License](#).

Address

University of Iowa
Roy J. and Lucille A. Carver College
of Medicine
Department of Ophthalmology and
Visual Sciences
200 Hawkins Drive
Iowa City, IA 52242

[Support Us](#)

Legal

Copyright © 2019 The University of
Iowa. All Rights Reserved
[Report an issue with this page](#)
[Web Privacy Policy](#) |
[Nondiscrimination Statement](#)

Related Links

[Cataract Surgery for Greenhorns](#)
[EyeTransillumination](#)
[Gonioscopy.org](#)
[Iowa Glaucoma Curriculum](#)
[Iowa Wet Lab](#)
[Patient Information](#)
[Stone Rounds](#)
[The Best Hits Bookshelf](#)

EyeRounds Social Media

Follow



Receive notification of new cases,
[sign up here](#)
[Contact Us](#)
[Submit a Suggestion](#)